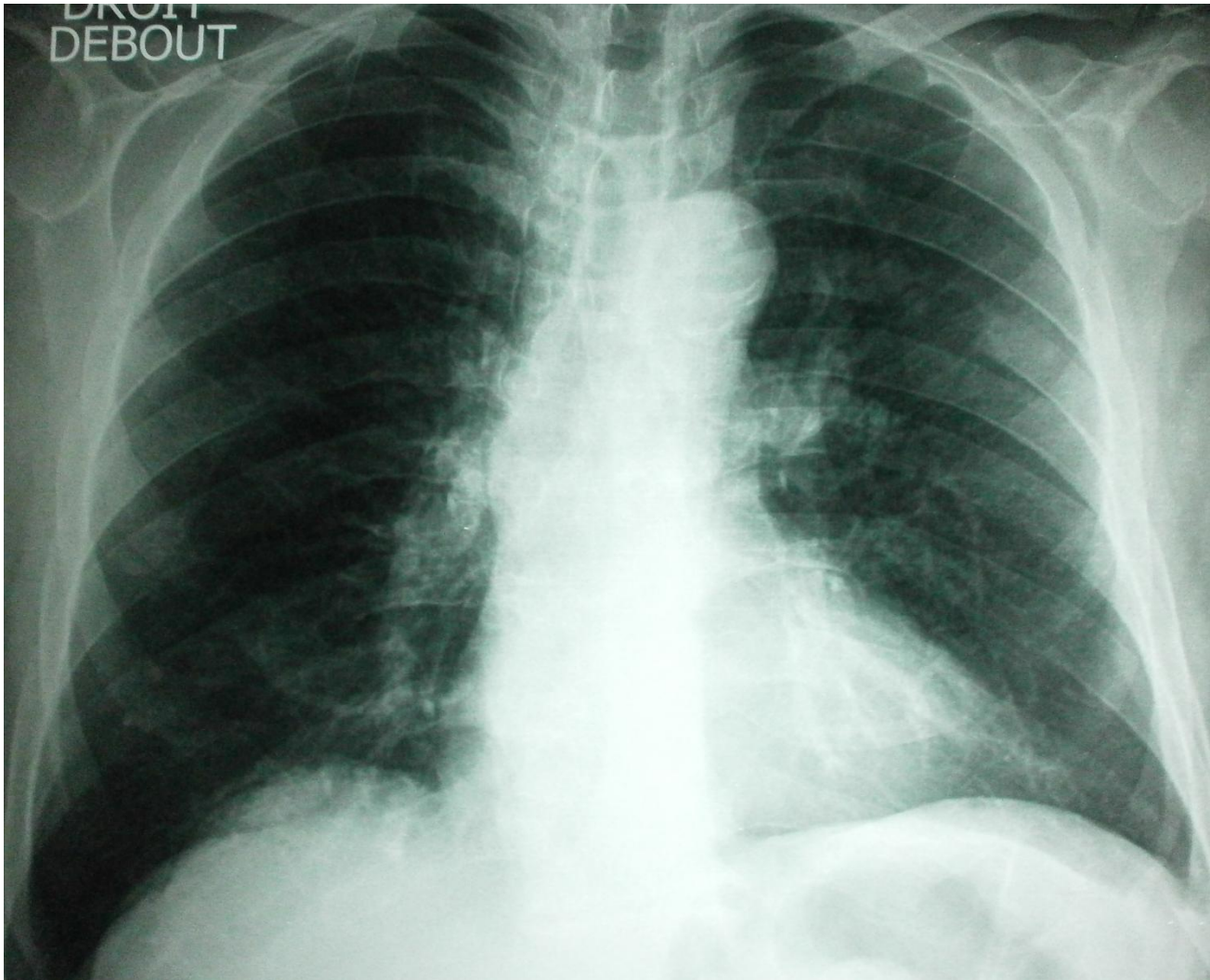
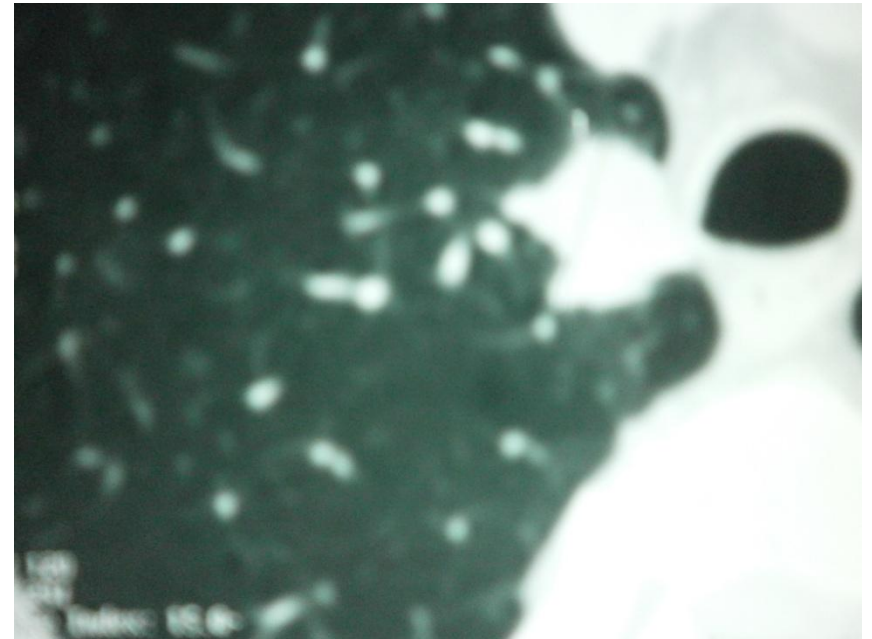
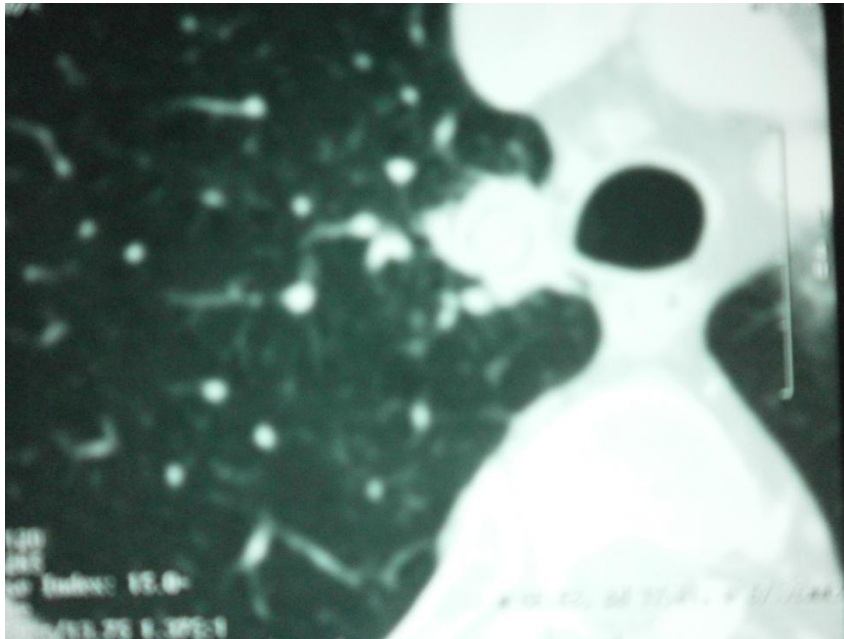


Homme de 70 ans; grand tabagique;
douleur thoracique gauche



**Que penser vous
de sa radio ?**

Il existe une tumeur paratracéale droite
aux scanner



DEBOUT

